



PATIENT

Max Ross

PRESENTING CLINICAL SIGNS

History: Chronic cough. Diagnosed with collapsing trachea. Cardiomegaly, no CHF.
-Abnormal PE/Chem/CBC/UA Results: ALP 440, ProBNP 730.

SPECIES

Canine

ECHOCARDIOGRAM FINDINGS

2D, m-mode, color flow and doppler imaging is available. The mitral valve is diffusely thickened with significant prolapse into the left atrial lumen. Suspect ruptured chord (see below). There is severe mitral regurgitation present. There is severe left atrial enlargement. There is moderate left ventricular dilation. Left ventricular systolic function is hyperdynamic. There is normal systolic flow velocity across the aortic valve. The aortic valve appears trileaflet with normal mobility. No aortic insufficiency. The main pulmonary artery is dilated. Moderate right atrial and right ventricular dilation. Mild right ventricular hypertrophy. The tricuspid valve is thickened with moderate tricuspid regurgitation. The tricuspid regurgitant velocity is elevated; PG >70mmHg. No pericardial/pleural effusion or cardiac masses are seen.

BREED

Yorkshire Terrier

SEX

Male Neutered

AGE

13 years

CARDIAC CHART

WEIGHT

8.2lbs

CANINE CARDIAC PARAMETERS	MR VMAX (m/s)	TR VMAX (m/s)	LA/AO (Boon method)	LA/AO (Heart Base; Swe)	FS (%)	EF (%)	EPSS (cm)
NORMAL PARAMETER	4.5-5.5	<2.7	1.3	<1.6	28-40	40-100	<0.6
PATIENT	5.0	4.3	1.8	2.4	68	95	0.08
CANINE CARDIAC PARAMETERS	HR (BPM)	AV VMAX (m/s)	PV MAX (m/s)	BODY WEIGHT (kg)	LA 2D short axis Base view (cm)	LVIDd Avg; 2D and m-mode short axis (cm)	LVIDs Avg; 2D and m-mode short axis (cm)
NORMAL PARAMETER	50-100	0.7-1.7	0.7-1.6	BELOW	BELOW	BELOW	BELOW
PATIENT	134	1.1	1.0	3.7	2.5	3.2	1.0
*Normal chamber parameters expressed as a mean value (SD)				3	1.27 (5.3)	2.46 (2.46)	1.36 (5.5)
BODY WEIGHT DEPENDENT PARAMETERS				5	1.40 (4.5)	2.74 (5.2)	1.60 (4.7)
<i>*Note: All measurements based upon multi-modal images and methods. An average value is reported.</i>				10	1.50 (3.8)	3.27 (3.5)	2.06 (3.1)
				15	1.83 (2.0)	3.71 (2.4)	2.43 (2.1)
				20	2.02 (1.9)	4.14 (2.2)	2.80 (2.0)
				25	2.18 (2.4)	4.48 (2.9)	3.10 (2.5)
				30	2.33 (3.3)	4.83 (3.9)	3.39 (3.4)
				35	2.48 (4.3)	5.17 (5.0)	3.69 (4.5)
				40	2.62 (5.2)	5.48 (6.1)	3.96 (5.4)
				50	2.88 (7.1)	6.07 (8.3)	4.46 (7.4)

INTERPRETED BY

Maggie Machen Lamy, DVM, DACVIM (Cardiology)

IMAGING PERFORMED BY

Potomac Mobile Veterinary Ultrasound

HOSPITAL NAME

Banfield Leesburg Village

REFERRING VET

Dr. Jarrett

INVOICE

21136

DATE

9/21/21

INTERPRETATION OF THE FINDINGS & FURTHER RECOMMENDATIONS

The cause of the murmur is chronic degenerative valve disease causing severe mitral and moderate tricuspid regurgitation. Severe left atrial and ventricular enlargement indicate the risk for spontaneous congestive heart failure is high. There is also concurrent significant pulmonary hypertension, which may indicate underlying pulmonary pathology as well in this coughing patient. Initiation of full cardiac support is recommended at this time as below including diuretics and Sildenafil, given a high risk for decompensation.



PATIENT

Max Ross

SPECIES

Canine

BREED

Yorkshire Terrier

SEX

Male Neutered

AGE

13 years

WEIGHT

8.2lbs

INTERPRETED BY

Maggie Machen Lamy,
DVM, DACVIM
(Cardiology)

IMAGING PERFORMED BY

Potomac Mobile
Veterinary Ultrasound

HOSPITAL NAME

Banfield Leesburg
Village

REFERRING VET

Dr. Jarrett

INVOICE

21136

DATE

9/21/21

A chronic cough in this patient with severe heart disease is likely multi-factorial in origin, however there is concern for progression to early CHF. Additional multi-factorial reasons include mainstem bronchi compression, and/or some degree of lower airway disease given the degree of right heart changes. Pending response to diuretic and supportive cardiac therapy, cough suppression (hydrocodone up to q4-6 hours) may also be helpful for QOL. Monitoring of sleeping breathing rates is recommended as the best way to screen for CHF at home.

The average survival of canine patients with this severity of disease and concern for CHF is 8-9 months on medications, however they generally are able to maintain a good quality of life. Going forward the risk will remain high for CHF (right or left-sided), development of arrhythmias/syncope and/or sudden death, and close monitoring is advised.

Elective anesthesia is not advised.

Omega fatty acid supplementation and mild salt restriction may also be of some long-term benefit. Monitor for development of a worsening cough, labored breathing, abdominal distention, exercise intolerance or collapse episodes. Monitoring of sleeping breathing rates is the best way to assess for development of cardiogenic edema going forward.

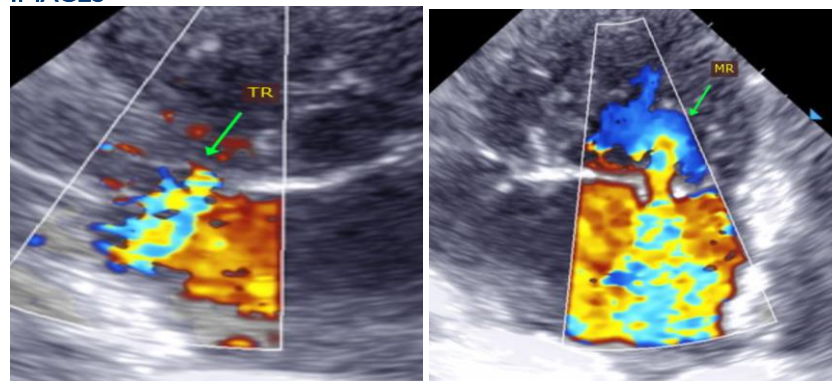
PLAN

Administer Lasix 1-2mg/kg PO q12h. Institute Pimobendan 0.3mg/kg PO q12h. Institute spironolactone 12.5mg PO q12h. Institute Sildenafil 1-2mg/kg PO q12h. If indicated, consider hydrocodone with homatropine, .2-.4mg tabs, PO up to q4-6 hours PRN. Pending BP >130mmHg, continue ACEI 0.5mg/kg PO q12h.

A renal panel is recommended in 10-14 days to ensure tolerance of medications, then every 3-4 months lifelong.

A recheck echocardiogram is recommended in 4-6 months to screen for progression, sooner if clinical signs arise/persist.

IMAGES





PATIENT

Max Ross

SPECIES

Canine

BREED

Yorkshire Terrier

SEX

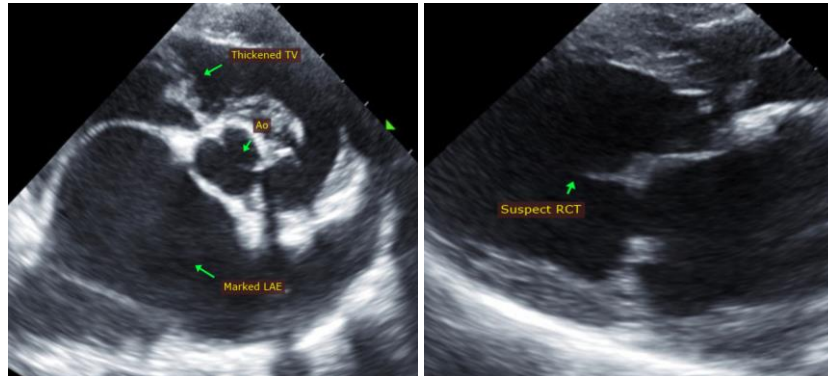
Male Neutered

AGE

13 years

WEIGHT

8.2lbs



The information and recommendations provided are based on the images presented by the referring veterinarian. No evaluation can be communicated regarding pathology that was not visible in the image/video clips provided.

Thank you for this referral. This report was generated using transcription software, and minor dictation errors may be present. If the clinical or image interpretation does not parallel your findings or if I can be of any further assistance, please contact me.

Maggie Machen Lamy, DVM
Diplomate of the American College of Veterinary Internal Medicine (Cardiology)
info@sonopath.com

INTERPRETED BY

Maggie Machen Lamy,
DVM, DACVIM
(Cardiology)

IMAGING PERFORMED BY

Potomac Mobile
Veterinary Ultrasound

HOSPITAL NAME

Banfield Leesburg
Village

REFERRING VET

Dr. Jarrett

INVOICE

21136

DATE

9/21/21